

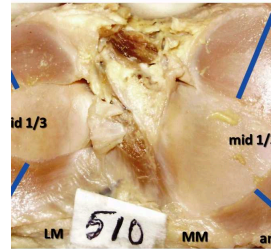
Nov 20, 2022

Version 1

Thickness and width of the menisci of adult knee joint, a cadaveric study V.1

DOI

dx.doi.org/10.17504/protocols.io.3byl4jjprlo5/v1



Murlimanju Virupakshamurthy¹, S Vikram², VANISHRI S. NAYAK³, Nandini P Bhat³, Mangala M. Pai¹, Rajanigandha Vadgaonkar¹, Latha V Prabhu¹, Sunil S Nayak³

¹Department of Anatomy, Kasturba Medical College, Mangalore, Manipal Academy of Higher Education, Manipal, India;

²Department of Anatomy, College of Medicine, King Khalid University, Abha-61421, Saudi Arabia;

³Department of Anatomy, Kasturba Medical College, Manipal-576104, Manipal Academy of Higher Education, Manipal, India



VANISHRI S. NAYAK

Create & collaborate more with a free account

Edit and publish protocols, collaborate in communities, share insights through comments, and track progress with run records.

Create free account

OPEN  ACCESS



DOI: <https://dx.doi.org/10.17504/protocols.io.3byl4jjprlo5/v1>

Protocol Citation: Murlimanju Virupakshamurthy, S Vikram, VANISHRI S. NAYAK, Nandini P Bhat, Mangala M. Pai, Rajanigandha Vadgaonkar, Latha V Prabhu, Sunil S Nayak 2022. Thickness and width of the menisci of adult knee joint, a cadaveric study.
protocols.io <https://dx.doi.org/10.17504/protocols.io.3byl4jjprlo5/v1> Version created by **VANISHRI S. NAYAK**

License: This is an open access protocol distributed under the terms of the **Creative Commons Attribution License**, which permits unrestricted use, distribution, and reproduction in any medium, provided the original author and source are credited

Protocol status: Working

We use this protocol and it's working

Created: November 19, 2022

Last Modified: November 20, 2022

Protocol Integer ID: 72986

Keywords: cadaveric knee joint, width of the menisci, adult cadaveric knee joint, joint meniscus, medial menisci, width of the knee, adult knee joint, meniscus transplantation, lateral menisci, meniscus, enlightening to the arthroscopic surgeon, allograft as the proper sizing, arthroscopic surgeon, knee, menisci, inaccurate sizing, complications due to the inaccurate sizing, proper sizing, cadaveric study background, vernier caliper

Abstract

Background: The goal is to determine the thickness and width of the knee joint meniscus at their different regions. The objective was to compare the dimensions at these regions and over the right and left sided specimens.

Methods: The present study will include 50 adult cadaveric knee joints and 100 menisci (50 medial menisci and 50 lateral menisci) were studied. The meniscus was distributed into anterior, middle and posterior parts. Thickness and width at the mid-point of these three parts were determined by using the Vernier caliper.

Conclusion: It is believed that this data is enlightening to the arthroscopic surgeon during the meniscus transplantation either by using synthetic material or allograft as the proper sizing of the meniscus is important to prevent the complications due to the inaccurate sizing.

Troubleshooting

Thickness and width of the menisci of adult knee joint: a descriptive cross-sectional observational study in cadavers

1 **Introduction**

The menisci are the fibrous cartilages which are present in the knee joint and deepen the articulation between the femur and tibia. They are prone for the tears because of the rotational injuries especially during the sports. There are marked differences in the contour and insertion between the lateral and the medial menisci, which are important in relation to the injury mechanisms (1). Variations of form and in particular, the thickness and width of the menisci can determine the possibility and kind of injury (2). The torn meniscus can be repaired by the allograft meniscal transplantation. Allograft meniscal transplantation is an increasingly popular treatment option for the symptomatic young patients with meniscus deficiency (3). The allograft or synthetic menisci have been suggested as a means to restore contact pressures following meniscectomy (4).

The successful clinical outcomes of these surgeries depend on how well an allograft matches the size and shape of the original meniscus which needs a set of parameters for describing the geometry of the medial and lateral menisci (5, 6). A mismatch may lead to failure of the allograft or subsequent development of degenerative changes (7). Therefore, understanding of the normal meniscal attachment is the basis for meniscal allograft transplantation (3). Donahue et al. (8) suggested an algorithm for selecting meniscal allografts that best match the size and shape of the damaged meniscus. They opined that the procedures used by tissue banks in selecting meniscal allografts at the time of surgical implantation should be improved. Though the appropriate graft sizing is critical for meniscal allograft transplantation, there are still no well accepted methods to choose the size-matched allograft (3). Accurate measurements of the meniscal characteristics would be of help as a tool for meniscal replacement and regeneration techniques (9).

2 **Aims and Objective**

The objective of the present study is to measure the width and thickness of the medial and lateral menisci in South Indian cadavers.

3 **Review of Literature**

The first meniscal allograft transplantation in human was reported by Milachowski and Wirth in 1984 (10). However the concept of meniscal replacement could be traced back to Lexer's and Gebhardt's work in 1916 and 1933 respectively, when fat tissue interposition arthroplasty was performed (10). The menisci are considered as main elements for perfect articulation among the osseous surfaces of tibia and femur (2, 11), performing mechanical functions like supporting the corporal weight, shock absorption, stabilization and rotational facilitation (2). The peripheral edges of the

menisci are convex, fixed and attached to the inner surface of the joint capsule, except where the popliteus is interposed laterally, these peripheral edges also are attached loosely to the borders of the tibial plateaus by coronary ligaments. The inner edges are concave, thin and unattached (12).

Prodromos et al. (13) proposed the contralateral MRI meniscal measurement as a gold standard to size menisci before transplantation. But it was opined that no imaging technique was accurate for measuring the individual meniscus dimensions, with only 35% of images measuring within 2 mm of actual meniscus dimensions (14). Van Thiel et al. (15) proposed a regression model which uses the height, weight and gender variables to accurately predict the required allograft meniscal size. According to Rico & Ayala (16), in an arthroscopic revision carried out to determine the topographic location of meniscal ruptures, the middle third part of the medial meniscus is the region more frequently injured, followed by the posterior third. In the study by Almeida et al. (2), it was reported that there was no statistically significant difference observed between the three parts of the medial menisci related to the thickness. They also reported that the middle third region of the lateral meniscus was the thickest in their specimens. Miller (17) reports that the medial meniscus is much larger in diameter, is thinner in its periphery and narrower in body. On the other hand, the medial meniscus is described by Didio (18) showing the posterior region quite wide and an anterior extremity sharp and thin. Miller (17) explained that the lateral meniscus is smaller in diameter, thicker at periphery, wider in body, and more mobile. The same author also explains that the radial tears occur most commonly in older patients at the midportion of the lateral meniscus. Figueroa et al. (19) observed that the lateral meniscus is more variable in its general configuration than the medial meniscus, appearing frequently wider in the body. However, Testut & Latarjet (20) and Didio (18) mentioned that the medial meniscus is a little wider than the lateral meniscus. According to Miller (17), the most common type of tear in the menisci is the longitudinal tear, usually involving the posterior segment of either the medial or the lateral meniscus.

4 **Methodology**

Study setting: Department of Anatomy, Kasturba Medical College, Manipal and Department of Anatomy, Kasturba Medical College, Mangalore

Study design: Descriptive Cross Sectional Study; Institutional Based Study

Study participants: Embalmed adult cadaveric knee joints, which are available in the department of anatomy will be utilized for this study. The genders of the specimens will not be taken into consideration.

Inclusion criteria: Embalmed adult cadaveric dissected knee joints, showing the intracapsular ligaments will be included.

Exclusion criteria: The knee joints exhibiting congenital anomalies and tears of the menisci will be excluded.

Study duration: 3 months

Sample size: 100 menisci (50 medial menisci and 50 lateral menisci, from 50 dissected cadaveric lower limbs)

Sampling method: The sample size is based on the previous literature available by a study from Egypt by El-Aasar et al. (21) in cadaveric samples.

Data collection methodology:

The measurements will be done by using the digital Vernier calliper of 0.02 mm accuracy.

The width and thickness of the medial and lateral menisci will be measured mid-point of the anterior 1/3, middle 1/3 and posterior 1/3 regions.

Data analysis: The data collected in this study will be presented as mean \pm SD and statistically analysed by using the online SPSS software. Statistical analysis between the sides and tibial plateau compartments will be performed by using paired samples t-test and repeated measures ANOVA. Two tailed p-values < 0.05 will be considered significant.

5 Implications

The intraarticular structures of the knee joint have been increasingly studied because of the advanced procedures like arthroscopy, computed tomography and magnetic resonance imaging. Also the investigation of these structures is important for the clinical diagnosis and surgical procedures (22). The present study will provide the morphometric data of the medial and lateral menisci with respect to their width and thickness at the anterior, middle and posterior regions. This data is important to the arthroscopic surgeons during the meniscus allograft transplantation.

6 References

1. Smillie IS. Injuries of the knee Joint. 4th ed. Living Stone, London, 1975
2. Almeida SKS, De Moraes ASR, Tashiro T, et al. Morphometric study of menisci of the knee joint. *Int J Morphol* 2004; 22:181-4
3. Wang YJ, Yu JK, Luo H, et al. An anatomical and histological study of human meniscal horn bony insertions and perimeniscal attachments as a basis for meniscal transplantation. *Chin Med J (Engl)* 2009; 122:536-40
4. Elsner JJ, Portnoy S, Guilak F, et al. MRI-based characterization of bone anatomy in the human knee for size matching of a medial meniscal implant. *J Biomech Eng* 2010; 132:101008
5. Pollard ME, Kang Q, Berg EE. Radiographic sizing for meniscal transplantation. *Arthroscopy* 1995; 11:684-7
6. Haut TL, Hull ML, Howell SM. Use of roentgenography and magnetic resonance imaging to predict meniscal geometry determined with a three-dimensional coordinate digitizing system. *J Orthop Res* 2000; 18:228-37
7. Dienst M, Greis PE, Ellis BJ, et al. Effect of lateral meniscal allograft sizing on contact mechanics of the lateral tibial plateau: an experimental study in human cadaveric knee joints. *Am J Sports Med* 2007; 35:34-42
8. Donahue TL, Hull ML, Howell SM. New algorithm for selecting meniscal allografts that best match the size and shape of the damaged meniscus. *J Orthop Res* 2006;

24:1535-43

9. Stone KR, Stoller DW, Irving SG, et al. 3D MRI volume sizing of knee meniscus cartilage. *Arthroscopy* 1994; 10:641-4
10. Milachowski KA, Weismeier K, Wirth CJ. Homologous meniscus transplantation. Experimental and clinical results. *Int Orthop* 1989; 13:1-11
11. Xavier SRH, Junior AGP, Filho TEPB. Lesões Menisco- Ligamentares do Joelho. In: Amatutuzzi MM, Hernandez AJ, Motta F. da. *Ortopedia e Trumatologia: Princípios e Prática*. 2nd ed. Porto Alegre, Artmed, 1998
12. Standring S. *Gray's Anatomy, The Anatomical Basis of Clinical Practice*. 39th ed. Spain, Churchill Livingstone, 2005; 1476-7
13. Prodromos CC, Joyce BT, Keller BL, et al. Magnetic resonance imaging measurement of the contralateral normal meniscus is a more accurate method of determining meniscal allograft size than radiographic measurement of the recipient tibial plateau. *Arthroscopy* 2007; 23:1174-9.e1
14. Shaffer B, Kennedy S, Klimkiewicz J, et al. Preoperative sizing of meniscal allografts in meniscus transplantation. *Am J Sports Med* 2000; 28:524-33
15. Van Thiel GS, Verma N, Yanke A, et al. Meniscal allograft size can be predicted by height, weight, and gender. *Arthroscopy* 2009; 25:722-7
16. Rico, E. G. C. & Ayala, C. E. A. Localización de las rupturas meniscales en nuestro medio. *Rev. Mex. Ortop.Traumatol.*, 11:10-3, 1997.
17. Miller, R. H. III. Knee injuries. In: Canale, S. T. & Beatty, J. H. (Eds.). *Campbell's Operative Orthopaedics*. Philadelphia, Mosby Elsevier, 2003. pp.2182-99.
18. Didio, L. J. A. *Tratado de Anatomia Aplicada*. 2a ed. Sao Paulo, Atheneu, 2002.
19. Figueroa, M.; Rios, A. L. L. & Narvaez, C. Menisco discoid interno: presentación de un caso y revisión de la literatura. *Rev. Colom. Ortop. Traumat.*, 3:155-8, 1999.
20. Testut, L. & Latarjet, A. *Tratado de Anatomía Humana*. 10a ed. Barcelona, Salvat, 1975.
21. El-Aasar HM, Nasralla MM, Kamal HA, Hussein HAM. Anatomical and morphometric study of the menisci of the knee joint in Egyptians. *Med. J. Cairo Univ.*, 86(8): 4475-4494, 2018.
22. Kale A, Kopuz C, Edyzer M, et al. Anatomic variations of the shape of the menisci: a neonatal cadaver study. *Knee Surg Sports Traumatol Arthrosc* 2006; 14:975-81